



# ACVIM

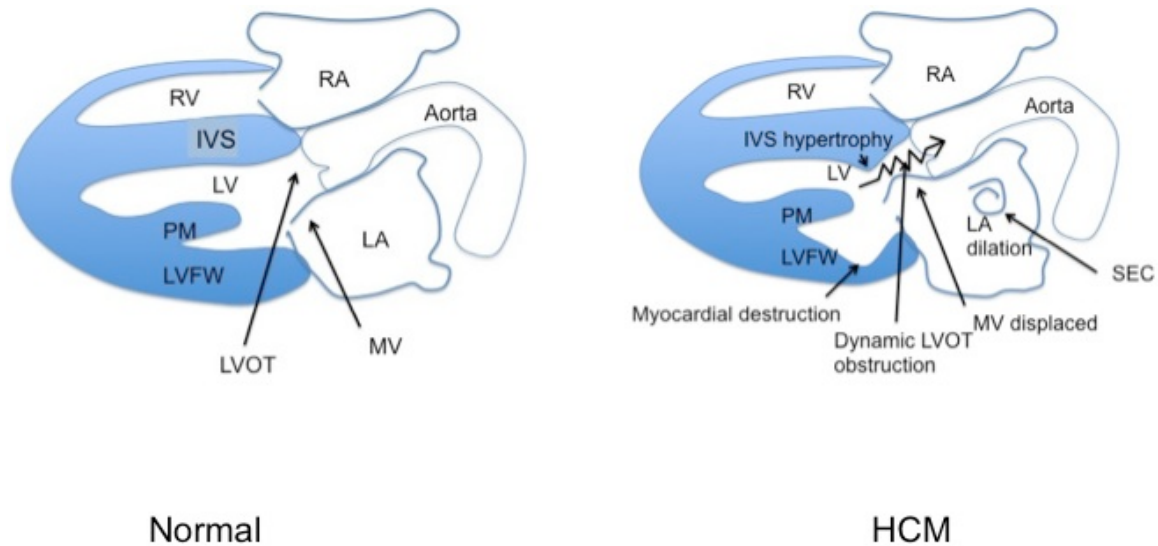
Cardiology  
Fact Sheet

## **ACVIM Fact Sheet: Hypertrophic Cardiomyopathy in Cats**

### ***Overview***

Hypertrophic cardiomyopathy (HCM) is one of the most commonly encountered heart disease in cats. This disease is characterized by an abnormal thickening (hypertrophy) of one or several areas of the walls of the heart, usually of the left ventricle. Hypertrophic cardiomyopathy is also present in humans and is caused by a variety of genetic anomalies of the cardiac muscle proteins. In cats, this disease is more prevalent in Ragdolls, Maine Coon, oriental breeds (Himalayan, Burmese, Sphynx, Persians) and Devon Rex, but it is also commonly diagnosed in Domestic Short Hair cats. A specific genetic defect has been identified in Ragdolls and Maine Coon involving a contractile protein: the myosin binding protein C. This disease is usually diagnosed in middle-aged cats. However, there is also a juvenile form affecting young cats (usually Ragdolls).

The impact of the thickening of the ventricular wall on the heart function is quite variable because there are many different forms of hypertrophy with this disease. If the hypertrophy is mild and focal, the cat may remain symptom-free for all his life. However, if the hypertrophy is severe, the ventricle will have a hard time distending, which leads to increased intra-cardiac pressure and congestive heart failure (CHF) with fluid build-up in or around the lungs. In some cases, the ejection of blood from the left ventricle can be impeded because the mitral valve is displaced against the inner wall of the ventricle, the septum, thus partially obstructing the passage. This phenomenon is called DOLVOT (Dynamic Obstruction of the Left Ventricular Outflow Tract) (Figure 1). In humans, this is associated with an increased risk of sudden death. Other complications of this disease include cardiac arrhythmias, leading to fainting or sudden death and clot formation in the left atrium. This clot may fragment, travel in the aorta and obstruct a major artery (typically the iliac artery, which brings blood to the hind limb). This phenomenon is coined FATE (Feline Arterial ThromboEmbolism). This disease can be progressive: with time, the left ventricle may dilate and its contractility may decline. Myocardial infarction may supervene, leading to destruction of areas of the cardiac muscle, a situation called remodeling.



**Figure 1:** Features of hypertrophic cardiomyopathy (HCM) in cats. On the left, a normal heart is represented. RV: right ventricle; LV: left ventricle, RA: right atrium, LA: left atrium; MV: mitral valve, LVOT: left ventricular outflow tract; IVS: interventricular septum; PM: papillary muscle; LFW: left ventricular free wall. On the right, the hypertrophy represented here affects the base of the septum but could affect any part of the left ventricular walls. The mitral valve is displaced against the septum, leading to dynamic obstruction of the LVOT (DOLVOT). (Art work: Eric de Madron)

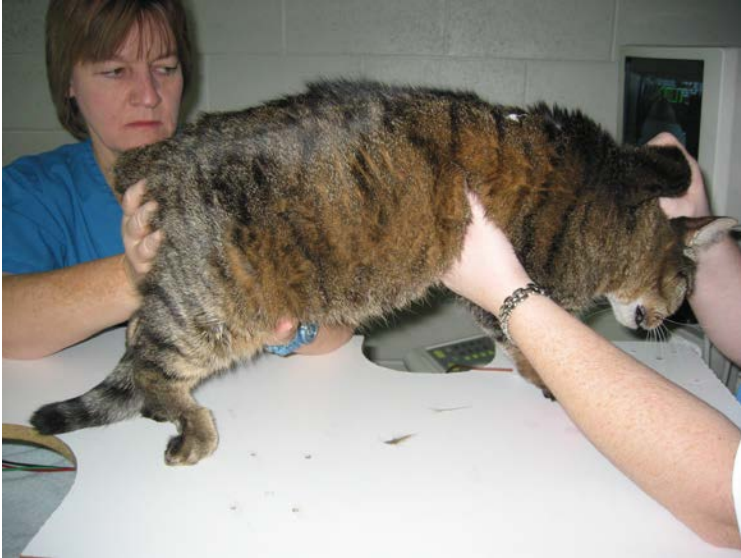### ***Signs & Symptoms***

Many cats with HCM are asymptomatic. The disease may be discovered when listening to the heart and abnormalities such as heart murmur(s), arrhythmias and/or extra heart sounds are heard. Other animals may have HCM screening (see below under screening) and abnormalities are noted.

When CHF occurs, with fluid build-up in (pulmonary edema) or around (pleural effusion) the lungs, the cat will experience breathing difficulties with increased breathing rate as well as labored breathing. Other non-specific symptoms such as vomiting and decreased appetite may also be present. Exercise intolerance, as seen in humans, is hard to assess in cats.

It is not uncommon to see the symptoms of CHF brought along by a triggering event such as anesthesia, IV fluids or stress.

With FATE (Feline Arterial ThromboEmbolism), there is sudden onset paralysis of one or several legs (hind or right front legs) (Figure 2). The affected leg becomes flaccid and is dragged. The extremity of these legs becomes cold and pale.



**Figure 2:** Arterial thromboembolism (FATE) in a cat with HCM. A blood clot originating from the heart has obstructed the distal aorta, blocking blood flow to the hind limbs. His hind legs are paralyzed with inability to rectify the position of his paws (knuckling). (Photo: Eric de Madron)

### ***Diagnosis***

The diagnosis of HCM relies on the documentation of the ventricular wall anomalies by cardiac ultrasound (echocardiography) and the exclusion of other non-genetic causes of hypertrophy such as hyperthyroidism and systemic hypertension. Other testing may include chest radiographs, electrocardiogram (ECG), blood pressure measurement and blood tests.

The goal of the cardiologist is not only to diagnose HCM, but also to establish risk factors to separate cats at low risk from cats at high risk of developing sudden death, CHF or FATE. Furthermore, periodic reassessments are required because of the progressive nature of some cases of HCM.

### **Screening**

#### ***Genetic testing***

The discovery of a specific genetic anomaly in Ragdolls and Maine Coon has allowed the development of a blood test. This test looks at the 2 copies of the gene affected (the one encoding myosin binding protein C). If the 2 copies are normal, risk of developing HCM is very low (but not completely absent, because mutations in other genes can be involved). If one copy is abnormal, then risk is moderate. If the 2 copies are abnormal, then the risk is high and the disease is likely to be severe. Echocardiography will become necessary to see if the genetic anomalies have translated into real disease. This test works only in these 2 breeds. It can be useful for breeders.

### *Periodic echocardiography*

This is the approach used in breeds at risk in which there is no genetic testing, such as Sphynx and Devon Rex.

### *NT-proBNP testing*

This blood test may help to identify asymptomatic cats with HCM but is associated with a lot of false positives. Its best value is to predict the ABSENCE of heart disease when it is in the normal range.

### ***Treatment & Aftercare***

In asymptomatic cats, no treatment has been proven to change the natural progression of the disease so far. However, there are some theoretical grounds behind the use of beta-blockers to attenuate the DOLVOT when present. In people, this has been shown to reduce the risk of sudden death. In cats, we do not know.

If the cat is thought to be at increased risk of FATE, then reduction of risk can be attempted by using blood thinners such as Clopidogrel (Plavix) alone or in combination with aspirin.

If the cat is in CHF, medications such as diuretics and ACEI (Enalapril, Benazepril) become required. Other medications stimulating contractility such as Pimobendan can be considered in selected cases.

### ***Prognosis***

The prognosis is quite variable and depends on the pattern of anomalies present in the heart, the degree of disturbances in the circulation of the blood inside the heart, the degree of dilation of the atria, the heart rhythm, and blood pressure. Cats with very stiff ventricles and profound disturbances of the blood circulation, very large atria, arrhythmias (such as atrial fibrillation), and low blood pressure have a poor prognosis. Juvenile forms of HCM, rapidly progressive, also carry a poor prognosis.

On the opposite end of the spectrum, cats with mild and focal hypertrophy without major blood circulation disturbances may live a completely normal life.

### ***Fact Sheet Author***

Eric de Madron, DVM, DACVIM (Cardiology), DECVIM (Internal Medicine)

© 2014

### ***Fact Sheet Disclaimer***

The fact sheets which appear on the ACVIM website are provided on an "as is" basis and are intended for general consumer understanding and education only. Any access to this information is voluntary and at the sole risk of the user.

Nothing contained in this fact sheet is or should be considered, or used as a substitute for, veterinary medical advice, diagnosis or treatment. The information provided on the website is for educational and informational purposes only and is not meant as a

substitute for professional advice from a veterinarian or other professional. Fact sheets are designed to educate consumers on veterinary health care and medical issues that may affect their pet's daily lives. This site and its services do not constitute the practice of any veterinary medical or other professional veterinary health care advice, diagnosis or treatment. The ACVIM disclaims liability for any damages or losses, direct or indirect, that may result from use of or reliance on information contained within the information.

ACVIM advises consumers to always seek the advice of a veterinarian, veterinary specialist or other qualified veterinary health care provider with any questions regarding a pet's health or medical conditions. Never disregard, avoid or delay in obtaining medical advice from your veterinarian or other qualified veterinary health care provider because of something you have read on this site. If you have or suspect that your pet has a medical problem or condition, please contact a qualified veterinary health care professional immediately.

ACVIM reserves the right at any time and from time to time to modify or discontinue, temporarily or permanently, these fact sheets, with or without notice.